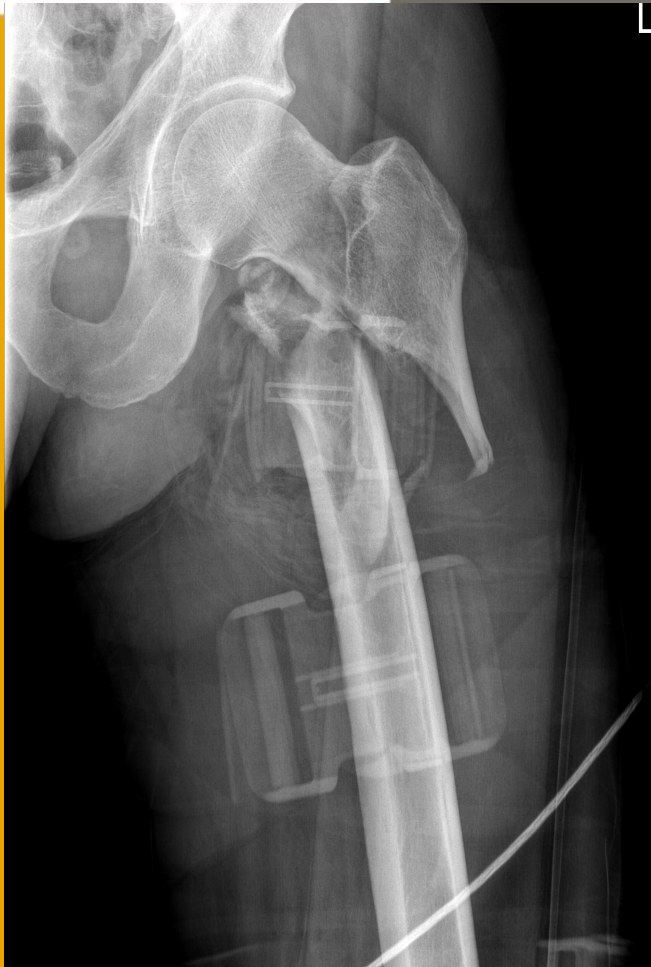

Case of the month: subtrochanteric 'reversed oblique' femoral fracture

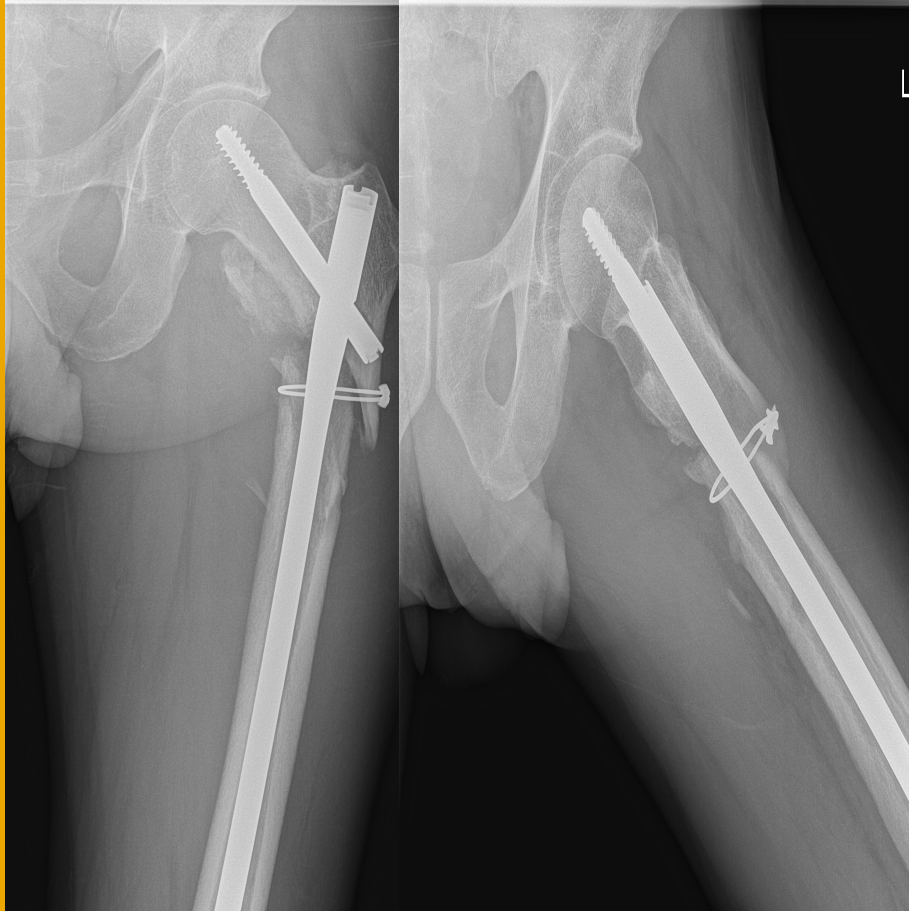
Dr Hans Feyen - St Dimpna
Hospital, Geel

Case of het month



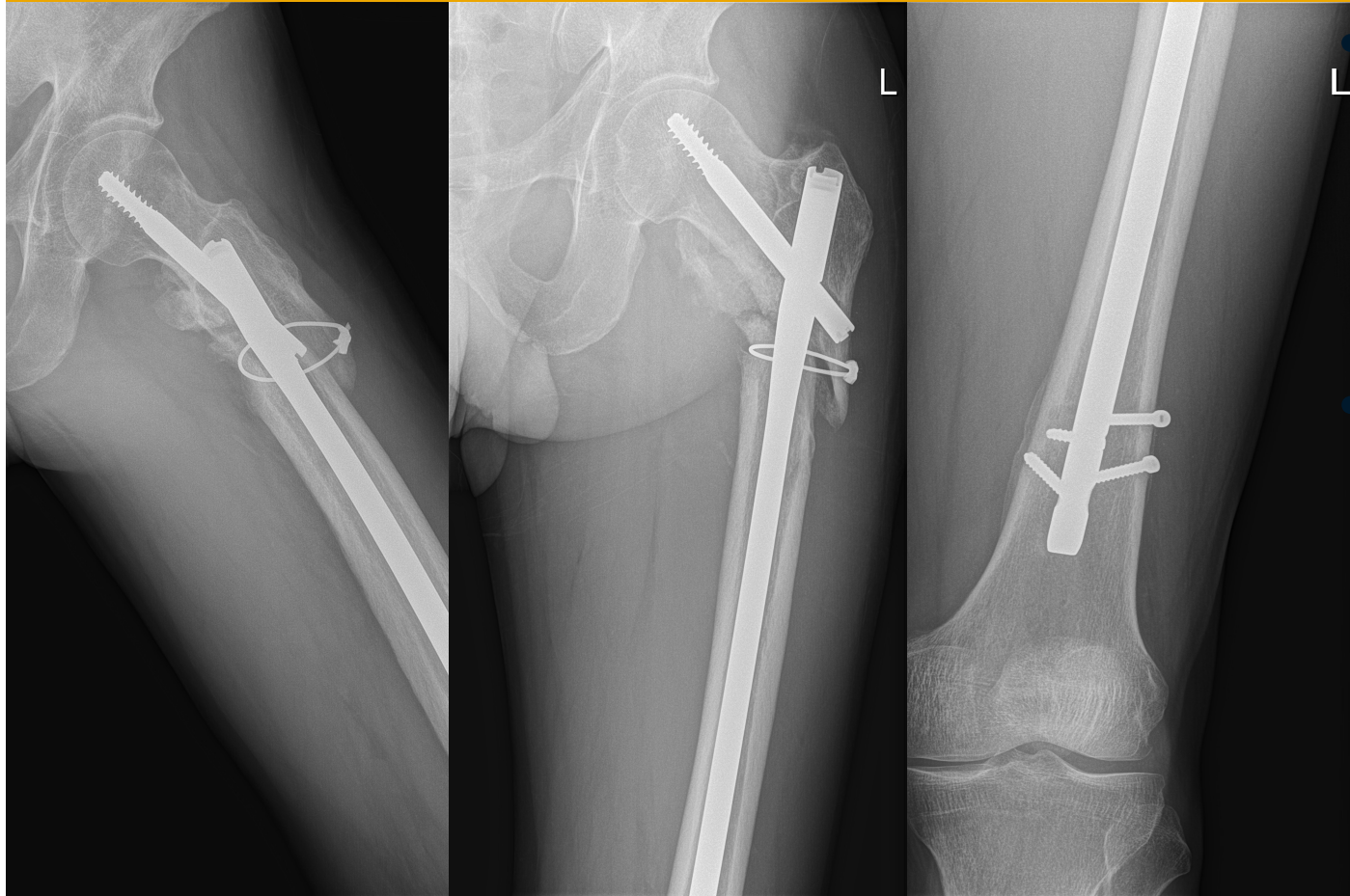
- 53 yr old bicylce rider hit by car
- Subtrochanteric 'reversed oblique' fracture
- AO classification 31-A3 fracture

Case of het month



- Subtrochanteric 'reversed oblique' fracture
- Treated with IM nailing and cerclage wiring
- Malreduction with distraction in fracture site

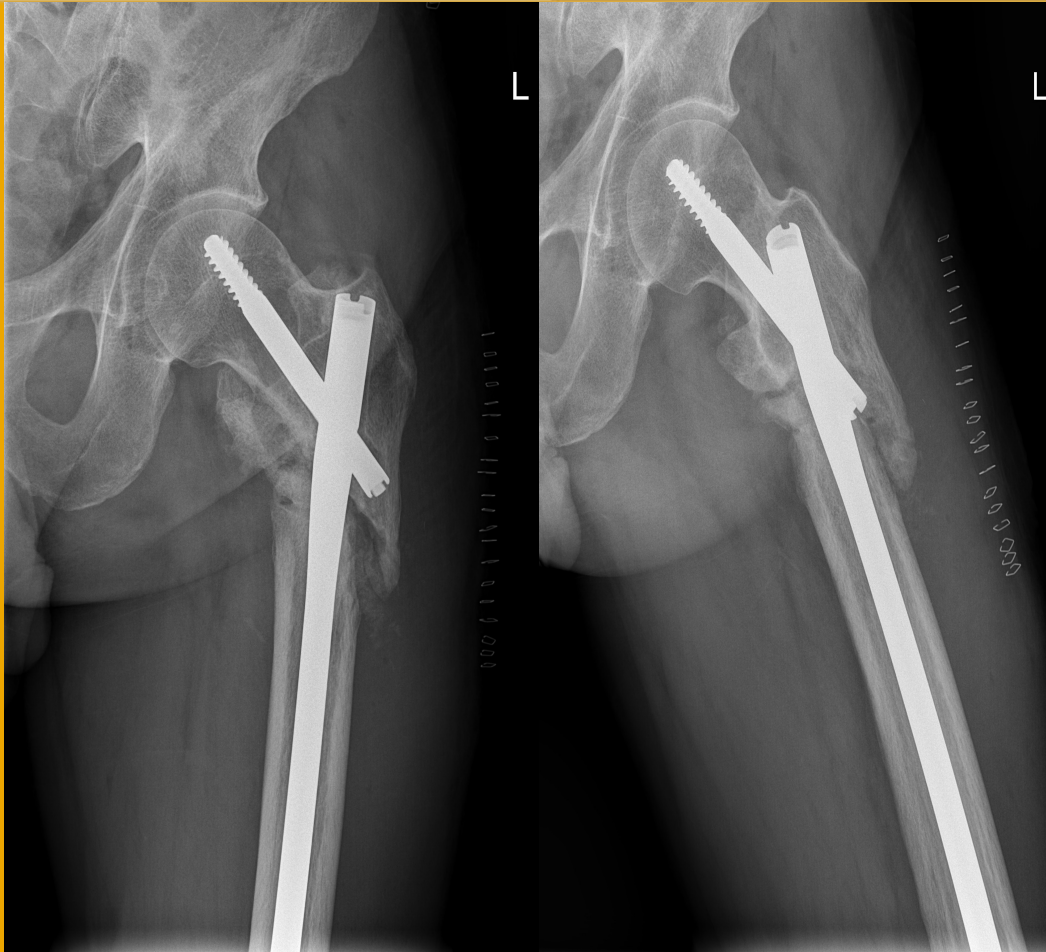
9 months post IM nailing



- - Fracture site compression through 'autodynamisation'

- -Non-union of fracture site, unable to walk without crutches

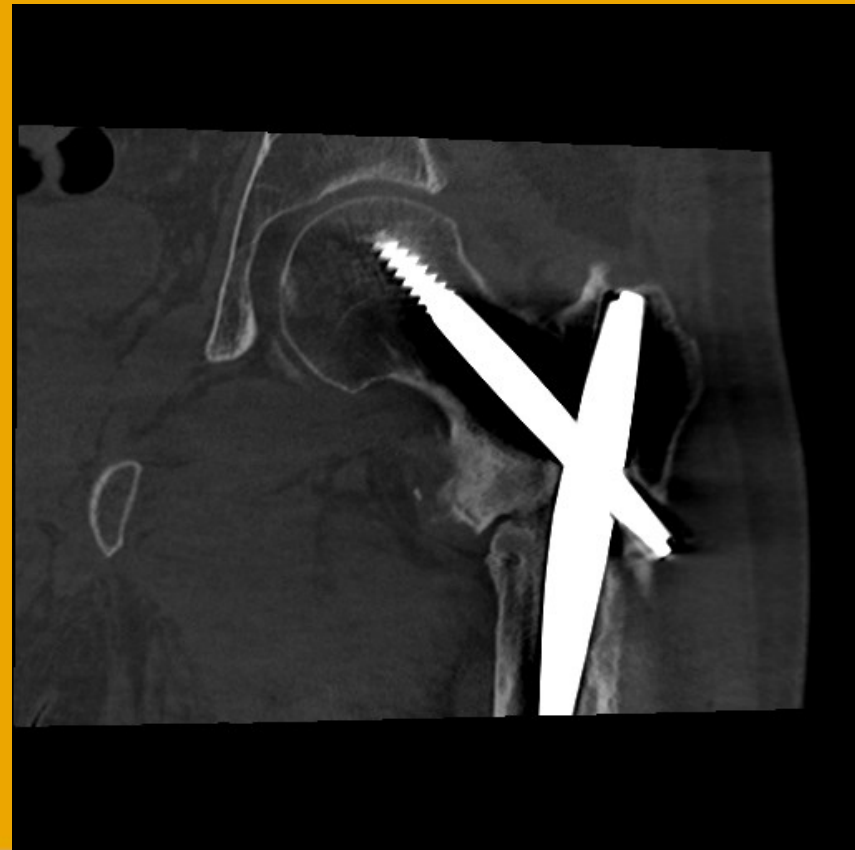
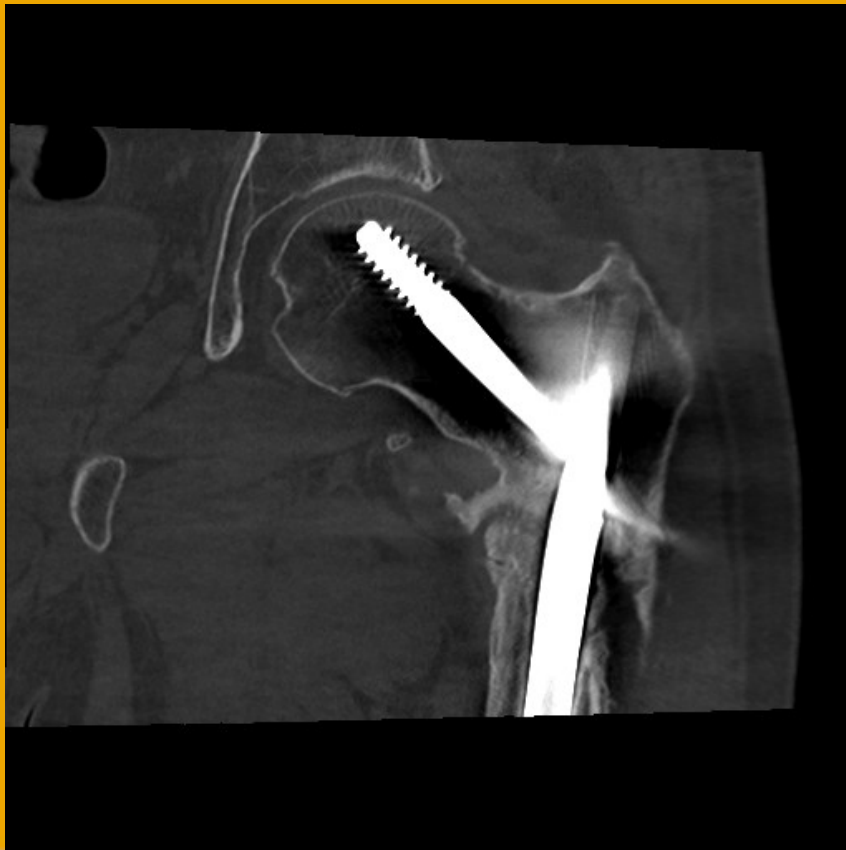
9 months post IM nailing



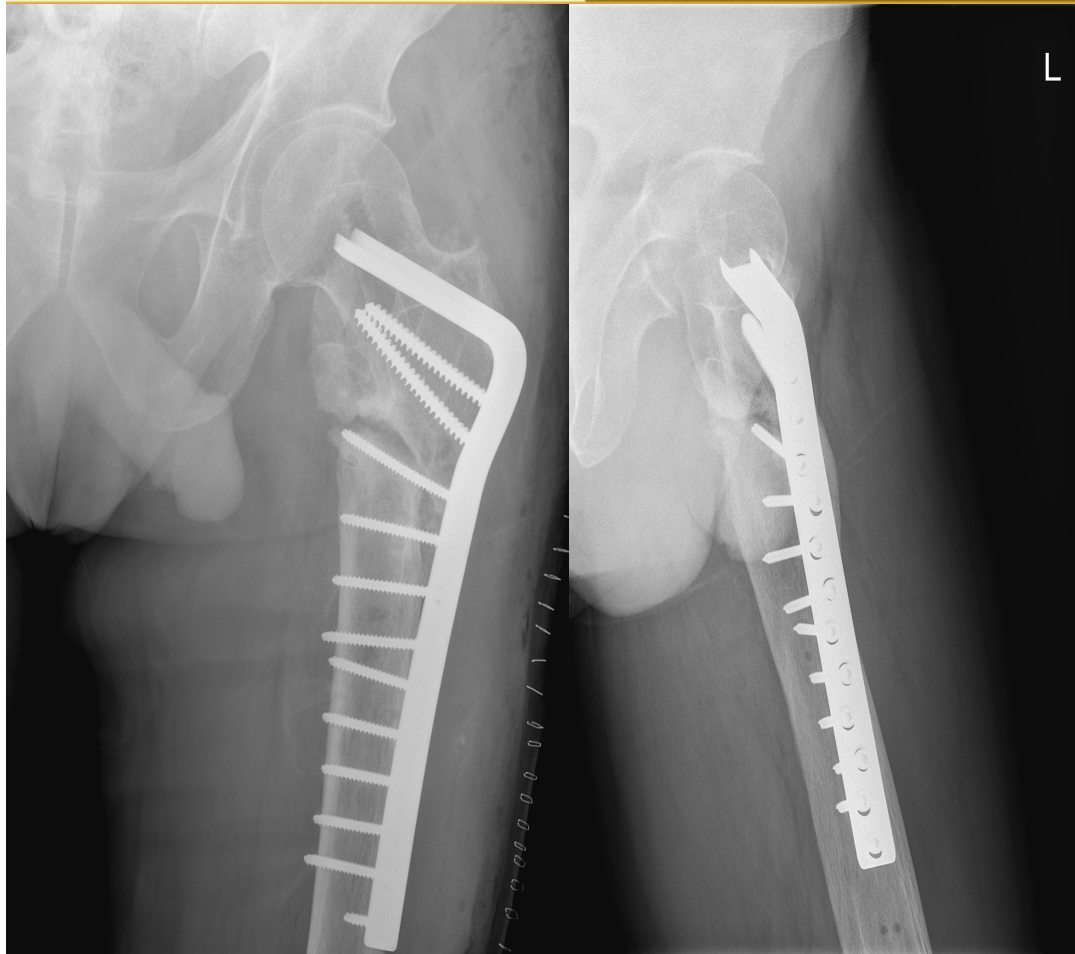
- Application of autologous bone graft
- Harvested from ipsilateral iliac crest
- IM nail left in situ

CT scan 6 months post bone graft:

Persistent non-union!



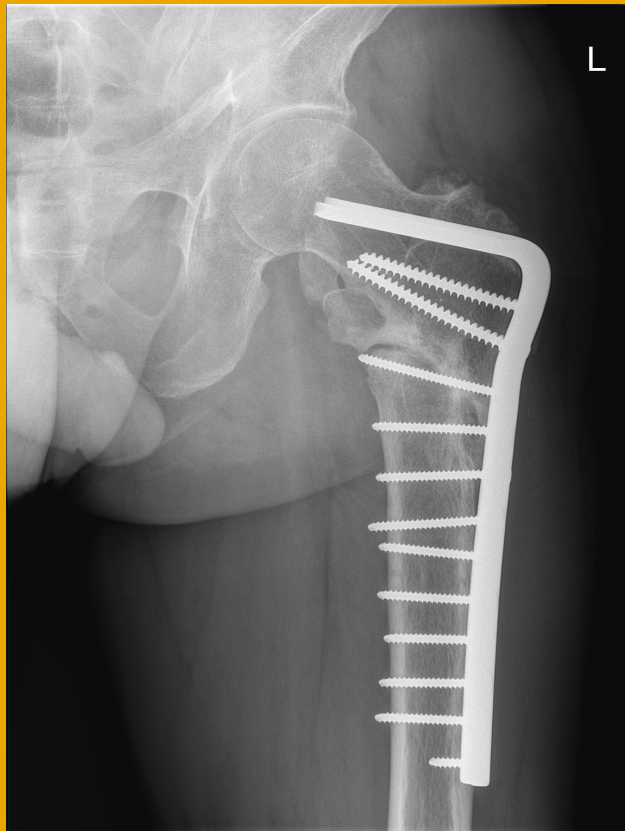
Treatment 15 months post trauma:



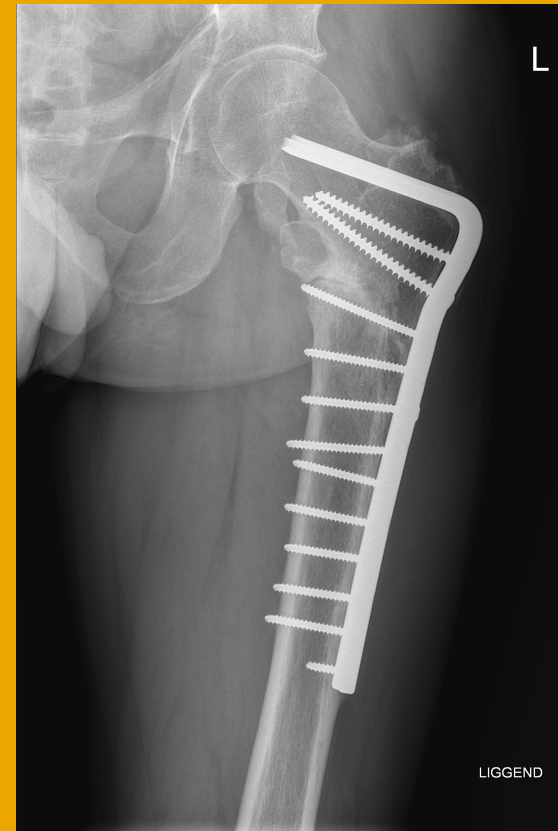
- Revision of IM nail to 95° blade plate
- Blade looks too short: longest blade available in Belgium
- Autologous bone graft application through RIA technique

Evolution after blade plate

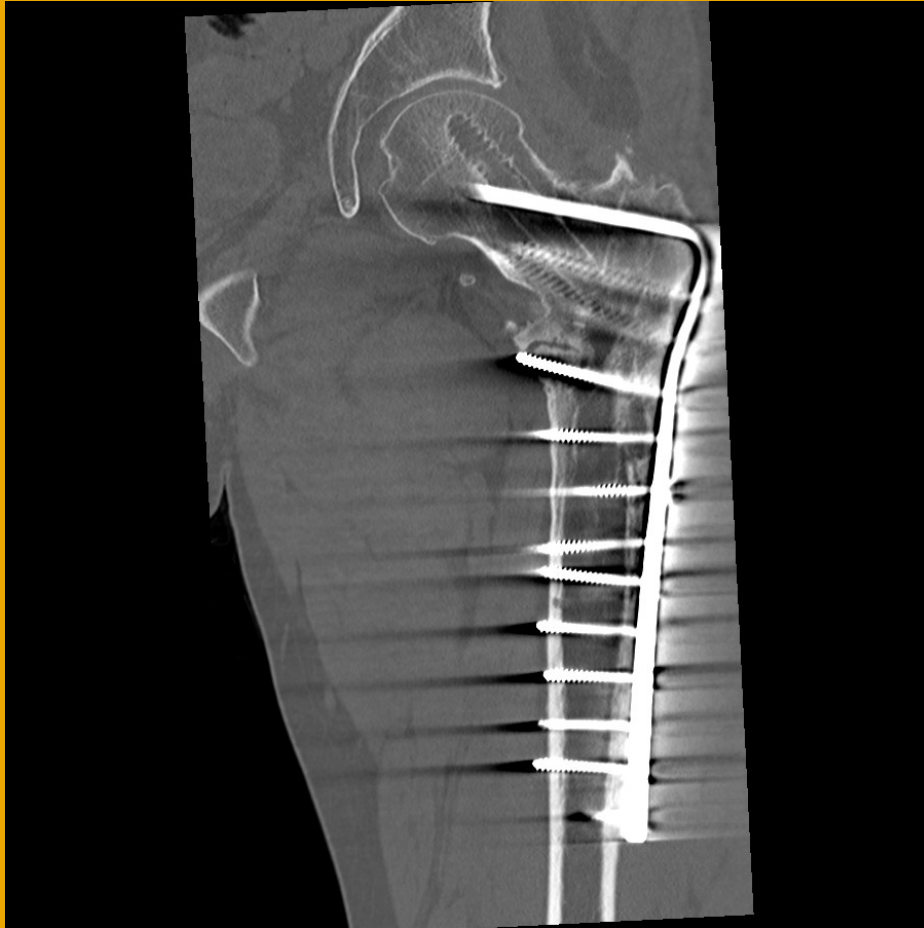
6 months post blade plate



1 year post blade plate



Evolution after blade plate



- Consolidation of fracture
- Patient walks without walking aid
- Slight limp
- Painfree